

Lesions of the Rectovaginal Septum: A Review

Rutgers University has made this article freely available. Please share how this access benefits you.
Your story matters. [\[https://rucore.libraries.rutgers.edu/rutgers-lib/50614/story/\]](https://rucore.libraries.rutgers.edu/rutgers-lib/50614/story/)

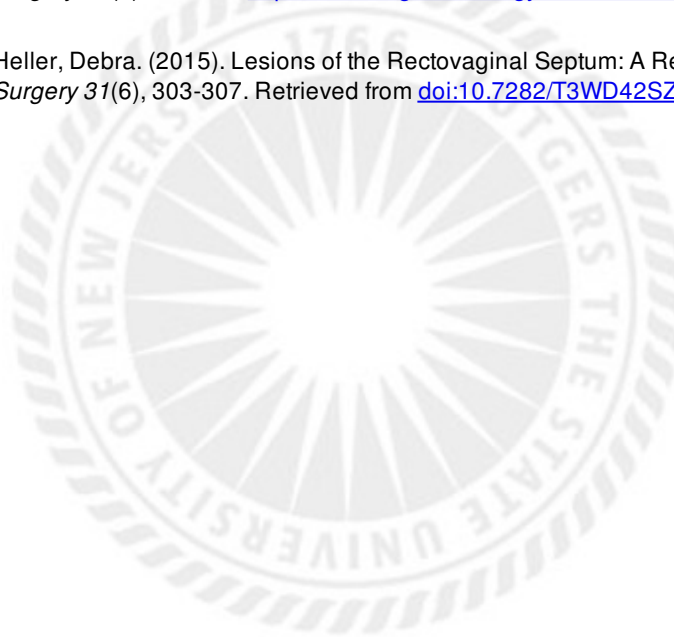
This work is an **ACCEPTED MANUSCRIPT (AM)**

This is the author's manuscript for a work that has been accepted for publication. Changes resulting from the publishing process, such as copyediting, final layout, and pagination, may not be reflected in this document. The publisher takes permanent responsibility for the work. Content and layout follow publisher's submission requirements.

Citation for this version and the definitive version are shown below.

Citation to Publisher Heller, Debra. (2015). Lesions of the Rectovaginal Septum: A Review. *Journal of Gynecologic Surgery* 31(6), 303-307. <http://dx.doi.org/10.1089/gyn.2015.0035>.

Citation to this Version: Heller, Debra. (2015). Lesions of the Rectovaginal Septum: A Review. *Journal of Gynecologic Surgery* 31(6), 303-307. Retrieved from [doi:10.7282/T3WD42SZ](https://doi.org/10.7282/T3WD42SZ).



Terms of Use: Copyright for scholarly resources published in RUcore is retained by the copyright holder. By virtue of its appearance in this open access medium, you are free to use this resource, with proper attribution, in educational and other non-commercial settings. Other uses, such as reproduction or republication, may require the permission of the copyright holder.

Article begins on next page

Lesions of the Rectovaginal Septum-A Review

Debra S. Heller, MD

From the Department of Pathology & Laboratory Medicine, Rutgers-New Jersey Medical School,
Newark, NJ

Address Correspondence to:

Debra S. Heller, MD

Dept of Pathology-UH/E158

Rutgers-New Jersey Medical School

185 South Orange Ave

Newark, NJ, 07103

Tel 973-972-0751

Fax 973-972-5724

hellerds@njms.rutgers.edu

Word count 1551

Running title: Lesions of the Rectovaginal Septum

Disclosures: none

Precis:

Lesions of the rectovaginal septum are reviewed.

Abstract:

Background:

The female rectovaginal septum may become involved by a variety of mass-like lesions, which may be challenging to providers who treat women.

Objectives:

To review the scope of lesions affecting the rectovaginal septum.

Methods:

A literature review was conducted. A Medline search was used, using the terms Vaginal diseases, Vaginal neoplasms, Rectal diseases, rectal neoplasms

Results:

Reported lesions of the rectovaginal were reviewed. Many of these lesions can be mistaken for each other clinically.

Conclusions:

A review of the scope of rectovaginal lesions is presented to assist in developing a differential diagnosis if a patient with such a lesion is encountered.

Key words: Vaginal diseases, Vaginal neoplasms, Rectal diseases, rectal neoplasms

Introduction:

Lesions presenting as masses of the rectovaginal septum are uncommon, and may be asymptomatic until quite large. This review aims to review lesions of the area(table 1), in order to provide assistance in developing a differential diagnosis, if such a patient is encountered.

Methods:

A literature review was conducted. A Medline search was used, using the terms Vaginal diseases, Vaginal neoplasms, Rectal diseases, rectal neoplasms

Results:

Reported lesions of the rectovaginal were reviewed. Many of these lesions can be mistaken for each other clinically.

Discussion:

Anatomy & Histology

The rectovaginal septum(rectovaginal fascia) is thought to derive from the urogenital sinus/vaginal plate, and is predominantly composed of fibroconnective tissue containing nerves and vessels(figure 1). Smooth muscle tissue present in this region is actually derived from the ventral rectum(1), and elastic tissue and vessels are present as well(2). Damage to the rectovaginal septum can lead to rectoceles, incontinence and constipation(1). The histology differs between the lower and upper portions(2). Nagata et al(2) studied elderly Japanese female cadavers, and found that the recto-vaginal interface was tight in the lower half, and loose in the upper half. This looseness in the upper portion may impact on high rectocele or enterocele repair, by providing minimal anchoring tissue to utilize in the repair. The authors also noted a variation among patients in the tissue components, suggesting individualization of repairs.

Congenital Anomalies

Although most cases of rectovaginal fistulas are acquired, congenital fistulas may occur, often in association with other anomalies in the region, such as rectosigmoid duplication(3).

A case of a villous adenoma that extended in continuity from rectum, through the rectovaginal septum and into the vaginal mucosa has been reported, and the authors postulated that this

circumstance is best explained by an underlying congenital malformation where there was communication through the rectovaginal septum(4).

Infections and Inflammations

Although usually lateral in location due to their embryologic distribution, Gartner's duct cysts derived from Wolffian duct remnants may present in the posterior vaginal wall, where they have been described in association with rectovaginal septal abscess formation(5). A rare case of echinococcosis has been described in the rectovaginal septum as an extremely rare etiology of a rectovaginal fistula(6). Abscesses may also derive from infected cryptoglandular cysts of the distal GI tract.

Rectovaginal fistulas

The most common etiologies for rectovaginal fistulas are prior obstetrical trauma, and Crohn's disease(7). Fistulas may also develop postoperatively after surgery for malignancy or endometriosis, due to devitalization of tissue. Although not always present, the finding of granulomatous inflammation is supportive of a diagnosis of Crohn's disease(figure 2). Fistulas may also occur secondary to intercourse, although this is much more likely with assault than consensual intercourse.

Benign Tumors and Tumor-like Lesions

Cysts

A variety of cysts may affect the rectovaginal septum, including endometriotic cysts and dermoid cysts. Inclusion cysts may arise from the posterior vaginal mucosa. This is not unexpected, as trauma is thought to be a contributor to the development of these cysts, and a history of episiotomy may be present. In one case, a squamous cell carcinoma of the vagina, extending into the rectovaginal septum arose in one of these squamous inclusion cysts(8).

Iatrogenic

Postoperative traumatic neuromas can be the cause of severe pain. A debilitating rectovaginal neuroma arising after a total vaginal hysterectomy and posterior colporrhaphy was described in a 32 year old female whose pain resolved after excision of the neuroma(9).

Endometriosis

The rectovaginal septum is a common location for deep endometriosis, potentially causing severe pain, and dyspareunia. It is often associated with fibrosis as well as proliferation of smooth muscle(10), and hence may present as a mass. Exceptionally rare rectal obstruction has been reported(10). Histologically, endometriosis, as elsewhere, is characterized by the presence of endometrial glandular epithelium and stroma. In the rectovaginal septum, this

may be accompanied by smooth muscle proliferation, sometimes nodular, leading some investigators to suggest that this type of deep endometriosis is more appropriately termed adenomyosis, although this and the existence of “adenomyomas” is debated(11,12). Rarely, this type of endometriosis may be associated with subsequently developing rectal injury with an intact perineum during childbirth, possibly due to loss of elasticity from the endometriosis(13).

It is well recognized that adenocarcinoma may arise in endometriosis, and while this is most commonly in the ovary, the second most common site, and most common extraovarian site is the rectovaginal septum(14). Histology may be papillary serous, endometrioid or clear cell adenocarcinoma(14), consistent with Müllerian origin.

Benign Mesenchymal Neoplasms

A variety of benign mesenchymal masses have been described arising in the rectovaginal septum, including fibromas, leiomyomas, “adenomyomas”, neurofibroma, fibromyoma, teratoma, lipoma and schwannoma(5,15). Such masses may be asymptomatic, or symptoms may be nonspecific, with impingement on adjacent organs such as bowel or bladder. An unusual case of a rectovaginal leiomyoma presenting as posterior vaginal wall prolapse was described(15). A case of gliomatosis peritonei involving the rectovaginal septum of an adolescent has been reported(16). This case was additionally unusual for occurring in association with a prior recurrent benign teratoma rather than an immature teratoma, the more usual association.

Malignant Neoplasms:

Carcinoma

Usual colorectal carcinomas may present as rectovaginal masses. In one unusual case, adenocarcinoma of colonic origin arose in a rectovaginal fistula in a setting of chronic Crohn disease(17). Immunohistochemistry is helpful in distinguishing adenocarcinomas of colonic origin from those of Müllerian origin.

Most primary malignancy arising in the RV septum is adenocarcinoma in association with endometriosis, and primary de novo Müllerian-derived carcinoma is very rare(18,19). Sampson's criteria(20) for attributing a neoplasm to endometriosis include that the neoplasm must be of compatible histologic origin, there must be no other primary, and endometriosis has to be present adjacent to the tumor. In many cases, it is possible that the neoplasm overruns adjacent endometriosis, obscuring it. Among theories for de novo carcinoma is Müllerian rest origin(18,21). Neoplasms of the RV septum can present with rectal or vaginal bleeding, acute urinary retention or other urinary symptomatology(18), abdominal pain or dyspareunia(21). Nelson et al(18) presented a case in a 47 year old woman who was initially diagnosed as having uterine prolapse. Histology was consistent with papillary serous carcinoma. Adenocarcinoma with squamous and clear cell differentiation has also been reported(21). These Müllerian carcinomas may also be of endometrioid histology, clear cell adenocarcinoma, or even possible adenosarcomas or carcinosarcomas, and may present with symptoms attributed to colon cancer, such as rectal bleeding, abdominal pain and/or constipation. A case of atypical proliferating("borderline") endometrioid tumor was also described in the rectovaginal septum,

where the tumor was thought to arise due to many years of unopposed estrogen therapy leading to malignant degeneration of endometriosis. Of interest, this lesion was androgen-producing(22). Due to the differences in therapy between these Müllerian tumors and primary colorectal cancer, it is important to be aware of this diagnosis (19,23). At least some of the adenocarcinomas arising in the rectovaginal septum appear to be less aggressive than the ovarian counterparts(24).

Secondary carcinomas may also extend through the rectovaginal septum, such as squamous cell carcinoma of the cervix(figure 3), vaginal carcinoma, rectal adenocarcinoma, or urachal carcinoma(figure 4). A rectovaginal septal metastasis may be the first sign of an unexpected neoplasm, such as the fallopian tube cancer described by Asai-Sato et al(25). The lesion was grossly unapparent in the fimbria, documented histologically, and showed matching p53 mutational analysis with the rectovaginal tumor.

Sarcoma

Because the rectovaginal septum is composed of mesenchymal tissue, a wide variety of unexpected soft tissue neoplasms may rarely occur. A case of leiomyosarcoma arising in the rectovaginal septum has been reported(26). The patient was 70 years old, and succumbed to her disease, which obstructed her urinary tract, and eroded into the posterior vagina.

Extra- gastrointestinal stromal tumors(eGISTs) have rarely been described in the rectovaginal septum. These tumors most commonly arise in the stomach, and are thought to originate from the interstitial cells of Cajal(27). They may behave in a benign or malignant fashion, but have recurred locally frequently in extra gastrointestinal locations(27). Tumor size, mitotic rate, cellularity and necrosis and Kit mutations have been utilized as prognostic factors for GISTs, but prognostic data for eGISTs are less clear(27,28). Most cases present in midlife patients. Grossly they are similar to leiomyomata, presenting as masses in the rectovaginal septum. Masses may be asymptomatic, or impact on urinary and bowel function, with possible urinary frequency and/or constipation(27). The similarity extends to microscopy, where the lesion is composed of spindle cells in fascicles, and hence eGIST needs to be considered. Immunohistochemistry will distinguish the two lesions, since leiomyomata stain for smooth muscle markers, while GISTs stain for CD 117(c-kit) and CD 34.

Aggressive angiomyxoma, usually described as a vulvar tumor with potential for pelvic extension, and locally aggressive behavior, can present in the rectovaginal septum(29).

Rare malignancies

A case of extraosseous Ewing's sarcoma was reported in a 45 year old patient, who refused surgery after chemotherapy(30). A case of rectovaginal mesothelioma was reported in a woman with a history of asbestos and beryllium exposure, and it was felt that the location of the neoplasm related to implantation during obstetrical injury, as beryllium was identified in the neoplasm as well as in water the patient douched with to treat her obstetrical lacerations(31).

Conclusions:

The rectovaginal septum may rarely be found to contain a mass. A knowledge of specific lesions of the region will be helpful if such a patient is encountered.

Acknowledgements: none

Disclosures: none

References:

- 1-Ludwikowski B, Hayward IO, Fritsch H. Rectovaginal fascia: An important structure in pelvic visceral surgery? About its development, structure, and function. *J Pediatr Surg.* 2002;37:634-8.
- 2-Nagata I, Murakami G, Suzuki D, Furuya K, Koyama M, Ohtsuka A. Histological features of the rectovaginal septum in elderly women and a proposal for posterior vaginal defect repair. *Int Urogynecol J Pelvic Floor Dysfunct.* 2007;18:863-8.
- 3-Prasil P, Nguyen LT, Laberge JM. Delayed presentation of a congenital recto-vaginal fistula associated with a recto-sigmoid tubular duplication and spinal cord and vertebral anomalies. *J Pediatr Surg.* 2000 ;35:733-5.
- 4-Ciano PS, Antonioli DA, Critchlow J, Burke L, Goldman H. Villous adenoma presenting as a vaginal polyp in a rectovaginal tract. *Hum Pathol* 1987;18:863-6.
- 5 -Brown KL, Segal AJ, Hurd GB. An unusual cyst of the vaginal wall; mucous cyst of mid-posterior vaginal wall, Gartner duct type, complicated by rectovaginal septum abscess. *An Surg* 1957;145:423-7.
- 6-Hakami M, Moslehy A, Mosavy SH. Echinococcosis of the rectovaginal septum. *Am J Proctol* 1976;27:43-4.
- 7-Nosti PA, Stahl TJ, Sokol AI. Surgical repair of rectovaginal fistulas in patients with Crohn's disease. *Eur J Obstet Gynecol Reprod Biol* 2013;17:166-70.
- 8-Němejcová K, Dundr P, Povýšil C, Sláma J. Primary vaginal squamous cell carcinoma arising in a squamous inclusion cyst: Case report. *Cesk Patol.* 2012 ;48:153-155.

9-Millheiser LS, Chen B. Severe vaginal pain caused by a neuroma in the rectovaginal septum after posterior colporrhaphy. *Obstet Gynecol* 2006;108:809-11.10 -Takai N, Ueda T, Nishida M, Nasu K, Narahara H. Bowel obstruction due to endometriosis in the rectovaginal septum. *Clin Exp Obstet Gynecol*. 2008;35:295-6.

11-Donnez J, Nisolle M, Casanas-Roux F, Bassil S, Anaf V. Rectovaginal septum, endometriosis or adenomyosis: laparoscopic management in a series of 231 patients. *Hum Reprod* 1995;10:630-5.

12-Anaf V, Simon P, Fayt I, Noel J-C. smooth muscles are frequent components of endometriotic lesions. *Hum Reprod* 2000;15:767-71.

13-Menzlova E, Zahumensky J, Gurlich R, Kucera E. Rectal injury following delivery as a possible consequence of endometriosis of the rectovaginal septum. *Int J Gynaecol Obstet*. 2014 ;124:85-6.

14-Goldberg MI, Ng ABP, Belinson JL, Hutson ED, Nordqvist SRB. Clear cell adenocarcinoma arising in endometriosis of the rectovaginal septum. *Obstet Gynecol* 1978;51s :38s-40s.

15-Cui N, Zormpa M, Lazarou G. A case of a large rectovaginal mass presenting as posterior vaginal wall prolapse. *Int Urogynecol* 2011;22:1185-8.

16-Dhingra KK, Mandal S, Khurana N, Mandal AK. Gliomatosis peritonei presenting as rectovaginal septum mass following recurrent mature ovarian teratoma. *Acta Oncologica* 2007;46:1035-6.

17- Chu M, Crist H, Zaino RJ Adenocarcinoma arising in a rectovaginal fistula in Crohn disease.

Int J Gynecol Pathol. 2010 ;29:497-500.

18-Nelson GS, Ghatage P, Mainprize TC, Duggan MA, Buie D, Nation JG. Primary carcinoma of the rectovaginal septum diagnosed as uterine prolapse. J Obstet Gynaecol Can 2005;27:1027-

3019-Guiou M, Hall WH, Konia T, Scudder S, Leiserowitz G, Ryu JK. Primary clear cell adenocarcinoma of the rectovaginal septum treated with concurrent chemoradiation therapy: a case report. Int J Gynecol Cancer 2007;18:1118-21.

20-Sampson JA. Endometrial carcinoma of the ovary arising in endometrial tissue of that origin. Arch Surg 192;10:1-72.

21-Giordano G, Bersiga A, Marchetti G, Melpignano M. Primary adenocarcinoma of the rectovaginal septum arising in pregnancy in the absence of endometriosis. Eur J Gynaec Oncol 2010;31:211-13.

22-Powell JL, Connor P, Henderson GS. Androgen-producing atypical proliferating endometrioid tumor arising in endometriosis. South Med J 2001;94:450-3.

23-Yang Q, Wang H, Cho HY et al. Carcinoma of Müllerian origin presenting as colorectal cancer: a clinicopathologic study of 13 cases. Ann Diagn Pathol 2011;15:12-18.

24-Yazbeck C, Poncelet C, Chosidow D, Madelenat P. Primary adenocarcinoma arising from endometriosis of the rectovaginal septum: a case report. Int J Gynecol Cancer 2005;15:1203-5.

25-Asai-Sata M, Hayashi H, Miyagi Y, Takahashi M, Shigeta H. An inconspicuous fallopian-tube carcinoma clinically manifested as a rectovaginal septal tumor: a pitfall for diagnosis and treatment. Int J Clin Oncol 2011;16:161-4.

26-Brown KL, Segal AJ, Hurd GB. Masses of the rectovaginal septum. *Am J Surg* 1960;90:309-15.

27-Vasquez J, Perez-Pena M, Gonzalez B, Sanchez A. Gastrointestinal tumor arising in the rectovaginal septum. *J Lower Gen Tract D* 2012;16:158-61.

28-Molina I, Seamon LG, Copeland LJ, Suarez A. Reclassification of leiomyosarcoma as an extra gastrointestinal stromal tumor of the gynecologic tract. *Int J Gynecol Pathol* 2009;28:458-63.

29-Tsuji T, Yoshinaga M, Inomoto Y, Taguchi S, Douchi T. Aggressive angiomyxoma of the vulva with a sole t(5;8)(p15;q22) chromosome change. *Int J Gynecol Pathol* 2007;26:494-6.

30-Petkovic M, Zamolo G, Muhvic D, Coklo M, Stifter S, Antulov R. The first report of Ewing's sarcoma in the rectovaginal septum. *Tumori* 2002;88:345-6.

31-Gold C. A primary mesothelioma involving the rectovaginal septum and associated with beryllium. *J Path Bact* 1967;93:435-42.

Legends:

Figure 1-Rectovaginal septum, composed of fibroconnective tissue(left), and adipose tissue(right). A nerve is seen at 3 o'clock.

Figure 2-Granuloma with multinucleated giant cells in a patient with Crohn's disease

Figure 3-Cervical squamous cell carcinoma, which had eroded through the rectovaginal septum, and is here seen adjacent to rectal glands.

Figure 4-Urachal adenocarcinoma, infiltrative the rectovaginal septum.