

Benign Tumors and Tumor-like Lesions of the Vulva

Rutgers University has made this article freely available. Please share how this access benefits you.

Your story matters. <https://rucore.libraries.rutgers.edu/rutgers-lib/50615/story/>

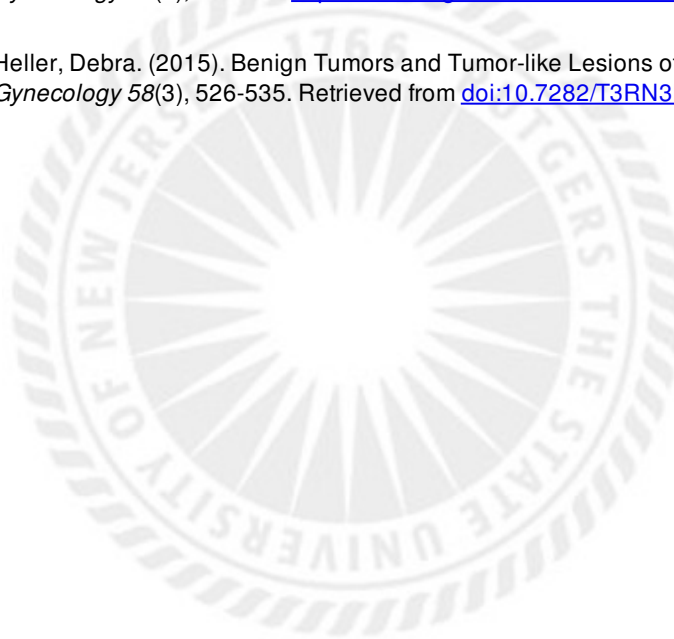
This work is an **ACCEPTED MANUSCRIPT (AM)**

This is the author's manuscript for a work that has been accepted for publication. Changes resulting from the publishing process, such as copyediting, final layout, and pagination, may not be reflected in this document. The publisher takes permanent responsibility for the work. Content and layout follow publisher's submission requirements.

Citation for this version and the definitive version are shown below.

Citation to Publisher Heller, Debra. (2015). Benign Tumors and Tumor-like Lesions of the Vulva. *Clinical Obstetrics & Gynecology* 58(3), 526-535. <http://dx.doi.org/10.1097/GRF.000000000000133>.

Citation to this Version: Heller, Debra. (2015). Benign Tumors and Tumor-like Lesions of the Vulva. *Clinical Obstetrics & Gynecology* 58(3), 526-535. Retrieved from [doi:10.7282/T3RN3B2N](https://doi.org/10.7282/T3RN3B2N).



Terms of Use: Copyright for scholarly resources published in RUcore is retained by the copyright holder. By virtue of its appearance in this open access medium, you are free to use this resource, with proper attribution, in educational and other non-commercial settings. Other uses, such as reproduction or republication, may require the permission of the copyright holder.

Article begins on next page

Benign Tumors and Tumor-like lesions of the Vulva

Debra S. Heller, MD

From the Department of Pathology & Laboratory Medicine, Rutgers-New Jersey Medical
School, Newark, NJ

Address Correspondence to:

Debra S. Heller, MD

Dept of Pathology-UH/E158

Rutgers-New Jersey Medical School

185 South Orange Ave

Newark, NJ, 07103

Tel 973-972-0751

Fax 973-972-5724

hellerds@njms.rutgers.edu

Funding: None

Disclosures: None

Abstract:

A variety of mass lesions may affect the vulva. These may be non-neoplastic, or represent benign or malignant neoplasms. A review of benign mass lesions and neoplasms of the vulva is presented.

Key words: Vulvar neoplasms, vulvar diseases, vulva

Introduction:

A variety of mass lesions may affect the vulva. These may be non-neoplastic, or represent benign or malignant neoplasms. Often an excision is required for both diagnosis and therapy. A review of the more commonly encountered non-neoplastic mass lesions and benign neoplasms of the vulva is presented. A familiarity with these lesions will be helpful if such a patient is encountered. Benign vulvar masses, including more rare ones are listed in table 1.

Cystic lesions:**Bartholin's Duct Cysts and Abscesses**

The paired Bartholin's ducts open onto the vestibule at the 4 o'clock and 8 o'clock positions (figure 1). If the duct openings become obstructed, a cyst results, or if the lesion becomes infected, often in association with gonorrhea or chlamydia, an abscess results. Most often, treatment of either a cyst or abscess does not provide a pathology specimen for histopathological evaluation. Abscesses may be drained, and cysts marsupialized. However, in some cases there is an excision, particularly if the woman is over 40, to rule out a carcinoma of the gland. The Bartholin's gland is composed of three epithelial types, mucinous columnar acini, transitional epithelial-lined ducts, and squamous epithelial orifices, although there may be mixed areas seen in the duct.

Skene's Duct Cysts

Periurethral mass lesions need to be distinguished from other lesions arising from the anterior vagina such as ectopic ureterocele, urethral diverticulum, urethral prolapse or malignancy. Immunohistochemical staining of Skene's glands with antibodies to prostatic antigens supports an analogy to the male prostate. Skene's duct cysts are most common in the third to fourth decade of life, but may be congenital or acquired, seen in infants and adolescents as well(1). Cysts of the Skene's ducts may be asymptomatic, or produce a mass effect, pain, discharge, dysuria, dyspareunia, or urinary stream diversion or obstruction. They may become infected as well. Urogenital evaluation including examination, imaging and endoscopic evaluation should be considered, due to the differential diagnoses. If small and asymptomatic, observation is an option, and some cysts resolve. Therapeutic options for these cysts have included antibiotics if infected, aspiration, marsupialization, partial excision, or ablation(2). The cysts are usually lined by squamous or transitional epithelium.

Epidermal Inclusion Cyst

Epidermal inclusion cysts can occur spontaneously, or after surgical procedures such as episiotomy, with trapping of epithelium. The cyst, lined by keratinizing stratified squamous epithelium, then accumulates keratinaceous debris, which grossly is cheesy, and may be foul-smelling(fig 2). This leads to the nodules being firm, and they may enlarge over time. These cysts do not need excision unless troublesome to the patient. Epidermal inclusion cysts may also affect the clitoris, where they may mimic

clitoromegaly. In a clitoral location, these are rarely spontaneous, more often associated with prior female genital mutilation(3).

Mucinous and ciliated cysts

Cysts, lined by ciliated or mucinous epithelium, are more common in the vagina, but can occur on the vulva. The origin is debated, and they may be of Müllerian, Wolffian, or urogenital sinus origin, or may represent metaplasia or heterotopia(4). A mucinous cyst may also represent a Bartholin's cyst, or a minor vestibular gland cyst. Location is sometimes but not always helpful in determining the cyst origin. Most of these cysts arise in the vestibule or labia minora. A positive mucicarmin stain will distinguish a mucinous cyst from a Gartner's duct cyst, particularly if the lining has flattened to a more cuboidal epithelium. Simple excision can be performed if necessary(fig 3).

Gartner's duct cyst

Gartner's duct cysts are derived from the mesonephric(Wolffian) ducts. They are located laterally, corresponding to the embryologic location of Gartner's ducts, and may appear in the vagina or out on the vulva. They are lined by a nonmucinous cuboidal lining, and may contain eosinophilic secretions.

Cyst of the Canal of Nuck

The Canal of Nuck is composed of the processus vaginalis, the peritoneum that accompanies the round ligament as it traverses the inguinal canal, ending in the vulva. Failure of closure of the processus vaginalis is thought to predispose to indirect inguinal hernia and/or cyst of the Canal of Nuck(5). A cyst of the Canal of Nuck is analogous to a male hydrocele, and may be thought to be an inguinal hernia preoperatively. Imaging studies may be helpful. Histologically, it is lined by mesothelium(fig 4). Treatment is surgical.

Solid lesions:

Lesions of skin and skin appendages:

Skin Tag:

Skin tags(acrochordons, fibroepithelial polyps) are usually easily recognized, and can be observed or removed if deemed necessary. The main differential diagnosis, condyloma accuminatum, can be distinguished by its koilocytosis, the cytopathic effect of HPV, which is not present in a skin tag.(fig 5).

Nevi

Nevi are common on the vulva. Benign nevi are of no clinical significance, but may be excised to rule out a malignant melanotic process, or for patient request(fig 6).

Seborrheic keratosis

These lesions can occur on the skin all over the body, and may present as a cosmetic issue. They are usually asymptomatic, but may raise concern if they are darkly pigmented. They have a characteristic “stuck on” greasy appearance clinically. Histologically there is hyperkeratosis, acanthosis, papillomatosis, and characteristic intraepidermal pseudohorn cysts of keratin(fig 7) .

Adenosis:

Adenosis has been associated with intrauterine exposure to diethylstilbestrol, but may arise spontaneously or occur after laser therapy or as a sequela of Stevens-Johnson syndrome(4). While usually vaginal, it can extend to the vestibule, and present with a wide variety of gross appearances, including nodularity. It may cause discomfort, bleeding or mucinous discharge. Histologically it is composed of cervical, tubal or endometrioid type glands(Fig 8). Many of these lesions resolve by squamous metaplasia.

Syringoma

Syringomas arise on the face, neck or chest, but may present as multiple small, skin colored pruritic papules on the vulva(6). They are derived from eccrine sweat glands. Therapies utilized have included observation, excision, electrodesiccation, laser, and cryotherapy. Histologically, they are composed of ductal structures with a characteristic comma shape (fig 9).

Hidradenoma papilliferum

Hidradenoma papilliferum, a benign neoplasm thought to be either of apocrine sweat gland or anogenital mammary-like gland origin, occasionally occurs on the vulva or perineum. It may be confused with adenocarcinoma by clinicians due to its tendency to ulcerate, and histopathologically, due to the closely packed glands which may mimic adenocarcinoma, but it is amenable to simple excision. The characteristic two-cell layer seen on histology distinguishes it from malignancy(fig 10).

Lesions of Anogenital Mammary Glands:

Anogenital mammary-like tissue, which was originally considered ectopic breast tissue along the milk line, is now thought to be part of the normal vulva, particularly in the sulcus between the labia majora and minora(7). As such, they can give rise to benign and malignant epithelial and stromal lesions usually seen in breast tissue(7).

Other Skin Adnexal lesions:

The vulvar epithelium contains abundant apocrine and eccrine glands, sebaceous glands, and pilosebaceous units in hair-bearing areas. As such, a wide variety of skin adnexal neoplasms that can occur elsewhere on the body can occur on the vulva. Most of these are reported in sporadic case reports. In a review from the Massachusetts General Hospital, Baker et al(8) found that most of the lesions were benign(70%), with a

predominance of hidradenoma papilliferum, syringoma, and cysts, but also there were rare cases of tubular adenoma, poroma, spiradenoma, cylindroma, sebaceoma, and trichoepithelioma among the benign lesions(8). Surgical excision is the usual therapy, and histopathological evaluation is necessary to confirm the diagnosis.

Mesenchymal and other Subcutaneous Lesions:

Hemangioma and Variants

Small capillary hemangiomas are common on the vulva, seen as single or multiple dome shaped purple papules, particularly in elderly women. Therapy is rarely needed, unless they bleed. Electrodesiccation has been utilized(4).

Lymphangioma circumscriptum is occasionally congenital, but is usually acquired after some underlying condition such as radiation therapy for gynecologic malignancy, or prior Crohn's disease(9). It is comprised of numerous small oozing vesicles(figure 11), which can be very distressing to the patient. It can be difficult to treat. Therapeutic options have included laser vaporization and excision(9)

Angiokeratomas are hemangiomatous lesions with overlying hyperkeratosis, easily treated with excision or electrodesiccation.

Lipoma

Lipomas, composed of adipocytes, may present as a mass lesion on the vulva. They are well circumscribed and lobulated, and histologically resemble normal adipose tissue, with

the addition of fibrovascular septae and circumscription. Observation or excision are options.

Fibroma

Vulvar fibromas may be small, but if large can be pedunculated. They are composed mainly of collagen with scattered fibroblasts, with overlying intact squamous epithelium. They are amenable to simple excision.

Leiomyoma

Leiomyoma may uncommonly arise in the vulva, most often arising on the labia majora, as a firm nodule. The origin is uncertain, but there is abundant smooth muscle in the region, including erectile tissue, vessel wall, round ligament, and erector pili muscle, which could potentially give rise to the lesion. The criteria for distinguishing a vulvar leiomyoma from a leiomyosarcoma is more strict than with its uterine counterpart, with worrisome features including size 5 cm or more, infiltration, 5 or more mitoses per ten high power fields, and grade 2-3 atypia(10). It has been suggested that if three of these criteria are met, the diagnosis is leiomyosarcoma, that two warrants a diagnosis of atypical leiomyoma, and that 1 or fewer is a leiomyoma(10) Other authors suggest that any mitotic activity, pleomorphism, or infiltrative margin are risks for local recurrence, which can occur many years later, and earn a lesion the designation of atypical leiomyoma(11).

Granular cell tumor

Granular cell tumor, a usually benign neoplasm thought to be of Schwannian origin has been reported on the vulva and perineum, although this is an unusual location(12). The lesion is composed of dermal cells with a distinct granular cytoplasm, with overlying pseudoepitheliomatous hyperplasia, which should not be mistaken for squamous cell carcinoma(figure 12). Lack of encapsulation may explain the occasional tendency for local recurrence(4). Due to the rare malignant behavior of this lesion, wide local excision should be considered.

Endometriosis:

Endometriosis involving the vulva and perineum is rare, and usually associated with an episiotomy scar(13), supporting the implantation theory of origin. Endometriosis of the vulva may present as a mass lesion, or may bleed or swell with the menstrual cycle. Treatment is excision. Histologically, both endometrial glandular epithelium and stroma must be present to confirm the diagnosis of endometriosis(fig 13). Less than 1% of cases of cutaneous endometriosis undergo malignant degeneration(14). Metastases from a uterine or ovarian primary must be considered in such a case.

Aggressive angiomyxoma

Aggressive angiomyxoma arising in the vulva or perineum may extend up into the pelvis, hence diagnostic imaging is important prior to surgery to delineate the extent of disease(15). Grossly the lesion has a gelatinous cut surface(figure 14). Histologically, aggressive angiomyxoma is deceptively bland in appearance, hypocellular with scattered spindle cells and vessels of mixed sizes in a myxoid matrix. Although usually a benign lesion, aggressive angiomyxoma is difficult to excise because of the extent of the lesion and the lack of circumscription, and also has a tendency to recur locally(15). Due to the potential hormonal sensitivity of these lesions, GnRh agonists have been utilized preoperatively to shrink lesions, and as an adjuvant therapy for incompletely excised or recurrent cases(15). The differential diagnosis includes angiomyofibroblastoma and other myxoid soft tissue neoplasms, soft tissue lesions that may be confused histopathologically. Distinction is important, as angiomyofibroblastoma is well circumscribed, and unlikely to recur after surgical excision. Aside from the circumscription in angiomyofibroblastoma, other distinguishing features from aggressive angiomyxoma include the presence of abundant delicate vessels, and a mix of hypo- and hypercellular areas in angiomyofibroblastoma.

.Perineal nodular induration:

Female equestrians may develop a reactive swelling known as perineal nodular induration, a lesion more commonly known in male bicycle riders(16). The case reported

by Devers et al occurred in a 55-year-old competitive equestrian. Excision of the 3.0 x 1.5 x 2.5 cm mass, which extended from the perineal fat close to the ischial tuberosity led to resolution of pain. Histologically, the poorly circumscribed lesion was composed of benign fibroadipose tissue with fibrosis and histiocytes. The spindle cells stain only for vimentin, with no evidence of differentiation towards a specific soft tissue(16). This lesion should not be confused with the unilateral labial hypertrophy termed “bicyclist’s vulva”(17), nor to “horse riders perineum”, perineal fibrosis and levator hypertrophy, which doesn’t produce a tumor-like swelling(18). Bicycling may also be associated with perineal numbness(16).

Pediatric benign tumors and tumor-like lesions involving the vulva:

Although a full discussion of pediatric vulvar lesions is beyond the scope of this review, a brief mention of condyloma accuminatum in the pediatric population is warranted. While abuse must be considered, it is also possible that pediatric anogenital condyloma can occur from vertical transmission, autoinoculation, heteroinoculation or fomites(19).

A female infant may be found to have a flesh-colored papule anterior to the anus that represents a lesion termed Infantile Perianal Pyramidal Protrusion(IPPP). The lesion may raise concern of condyloma accuminatum(20), and hence it is important to be aware of this entity. IPPP is present at birth or shortly thereafter, does not grow or multiply, and is asymptomatic. In addition to condyloma accuminatum, the differential includes molluscum contagiosum, skin tag, hemorrhoid, rectal prolapse, nevus, hemangioma, or

regional swelling after trauma(20). IPPP is not thought to relate to abuse or trauma, but may relate to constipation, and has been suggested to have some association with lichen sclerosus(20). It often resolves spontaneously(20).

Conclusion:

A large number of benign nodular lesions may involve the vulva. A familiarity with the spectrum of possible lesions will be helpful when a patient presents with a vulvar mass lesion.

References:

- 1-Shah SR, Biggs GY, Rosenblum N, Nitti VW. Surgical management of Skene's gland abscess/infection: a contemporary series. *Int Urogynecol J* 2013;23:159-64.
- 2- Ejnès L, Toullalan O, Fayad S, Bongain A, Reveille MD, Gillet JY. Very large Skene's duct cyst. *Acta Obstet Gynecol Scand* 2004;83:598.
- 3-Al-Ojaimi EH, Abdulla MM. Giant epidermoid inclusion cyst of the clitoris mimicking clitoromegaly. *J Low Genit Tract Dis.* 2013;17:58-60.
- 4-Heller DS, Wallach, RC, eds. *Vulvar Disease, a Clinicopathologic Approach.* Informa Healthcare, 2007.p135-88.
- 5-Choi YM¹, Lee GM, Yi JB, Yoon KL, Shim KS, Bae CW, Choi SI, Kim HC. Two cases of female hydrocele of the canal of nuck. *Korean J Pediatr.* 2012 ;55:143-46.
- 6-Kavala M¹, Can B, Zindanci I, Kocatürk E, Türkoğlu Z, Büyükbabani N, et al. Vulvar pruritus caused by syringoma of the vulva. *Int J Dermatol.* 2008;47:831-32.
- 7-Kazakov DV, Spagnolo DV, Kacerovska D, Michal M. Lesions of anogenital mammary-like glands: an update. *Adv Anat Pathol* 2011;18:1-28.
- 8-Baker GM, Selim A, Hoang MP. Vulvar adnexal lesions. A 32 year, Single-institution review from the Massachusetts General Hospital. *Arch Pathol Lab Med* 2013;137:1237-46.
- 9- Shetty V, Venkatesh S Acquired lymphangioma circumscriptum of the vulva. *Int J Gynaecol Obstet* 2012;117:190.
- 10-Nielen GP, Rosenberg AB, Koerner FC, Young RH, Scully RE. Smooth muscle tumors of the vulva. A clinicopathological study of 25 cases and review of the literature.

Am J Surg Pathol 1996;20:779-93.

11-Nucci MR, Fletcher CDM. Vulvovaginal soft tissue tumors: update and review.

Histopathol 2000;36:97-108.

12-Apisanthanarax P. Granular cell tumor. An analysis of 16 cases and review of the literature. J Am Acad Dermatol 1981;5:171-82.

13-Cheng DL, Heller DS, Oh C. Endometriosis of the perineum; report of two new cases and a review of literature. Eur J Obstet Gynecol Reprod Biol. 1991;42:81-84.

14-Chene G, Darcha C, Dechelotte P, Mage G, Canis M. Malignant degeneration of perineal endometriosis in episiotomy scar, case report and review of the literature. Int J Gynecol Cancer 2007;17:709-14.

15-Bai HM, Yang JX, Huang HF, Cao DY, Chen J, Yang N, et al. Individualized managing strategies of aggressive angiomyxoma of female genital tract and pelvis. Eur J Surg Oncol. 2013;39:1101-08.

16-Devers KG, Heckman SR, Muller C, Joste NE. Perineal nodular induration: a trauma-induced mass in a female equestrian, Int J Gynecol Pathol 2010;29:398-401.

17-Leibovitch I, Mory Y. The vicious cycling: bicycling related urogenital disorders. Eur Urol 2005;47:277-87

18-Crepin G, Biserte J, Cosson M. The female urogenital system and high level sports. Bull Acad Natl Med 2006;190:1479-83.

19-Stefanaki C, Barkas G, Valari M, Bethimoutis G, Nicolaidou E, Vosynioti V, Kontochristopoulos G et al. Condylomata acuminata in children. Pediatr Inf D 2012;31:422-24

20.-Casey AS, Gehris RP. A 9-month-old girl with an isolated sessile growth on her perineum. *J Pediatr Adolesc Gynecol* 2007;20:35-37.

Table 1- **Benign Tumors and Tumor-like lesions of the Vulva**

Cystic lesions:

- Bartholin's Duct Cysts and Abscesses
- Skene's Duct Cysts
- Epidermal Inclusion Cyst
- Mucinous and ciliated cysts
- Gartner's duct cyst
- Cyst of the Canal of Nuck
- Perineal Hernia

Solid lesions:

Epithelial lesions

- Skin tag
- Nevus
- Seborrheic keratosis
- Adenosis
- Syringoma
- Hidradenoma papilliferum
- Anogenital mammary-like glands and associated lesions

Mesenchymal and other Subcutaneous lesions

- Endometriosis
- Hemangioma
- Fibroma
- Lipoma
- Granular cell tumor
- Leiomyoma
- Angiomyofibroblastoma
- Aggressive angiomyxoma
- Teratoma
- Osteochondroma
- Neurofibroma
- Schwannoma
- Perineal nodular induration

Legends:

Figure 1- Bartholin's duct cyst may be suspected by the location of the cyst in the region of the duct opening. **Copyright Libby Edwards, MD. Used with permission. All permission requests for this image should be made to the copyright holder.**

Figure 2- Epidermal inclusion cyst. Grossly, these lesions are firm, and yellowish, due to their contents(2A). **Copyright Libby Edwards, MD. Used with permission. All permission requests for this image should be made to the copyright holder.**

They are lined by keratinizing squamous epithelium(2B).

Figure 3- Mucinous cyst-The lining is composed of a simple mucinous columnar epithelium. The contents are mucinous.

Figure 4 Cyst of Canal of Nuck can mimic an inguinal hernia(4A) **Copyright Libby Edwards, MD. Used with permission. All permission requests for this image should be made to the copyright holder.** The lesion is lined by mesothelium(4B).

Figure 5 Skin tag-Typical skin tag lined by squamous epithelium. **Copyright Libby Edwards, MD. Used with permission. All permission requests for this image should be made to the copyright holder.**

Figure 6 Nevus-Intradermal nevus, showing nevus cells in dermis.

Figure 7 Seborrheic keratosis-Typical pseudohorn cysts composed of keratin

Figure 8 Adenosis, undergoing squamous metaplasia

Figure 9 Syringoma, showing typical comma-shaped tubules.

Figure 10 Hidradenoma papilliferum can mimic carcinoma grossly when there is ulceration(10A) **Copyright Libby Edwards, MD. Used with permission. All permission requests for this image should be made to the copyright holder.** , as well as histologically due to crowded glands(10B), although the benign nature of the lesion is revealed by the 2 cell layer.

Figure 11 Lymphangioma circumscriptum-The multiple weeping vesicles are composed of dilated lymphatic spaces.

Figure 12-Granular cell tumor. Overlying epithelium showing pseudoepitheliomatous hyperplasia with increased rete pegs(right). The neoplasm shows a granular cytoplasm(inset).

Figure 13 Endometriosis-Endometrial glandular epithelium and stroma must be present to render this diagnosis.

Figure 14 –Aggressive angiomyxoma showing gelatinous cut surface(14A). The lesion is not histologically well circumscribed. It is histologically of a deceptively bland hypocellular lesion(14B) composed of mesenchymal cells and vessels.